

# Sphenopalatine Ganglion Neuralgia

## Diagnosis and Treatment

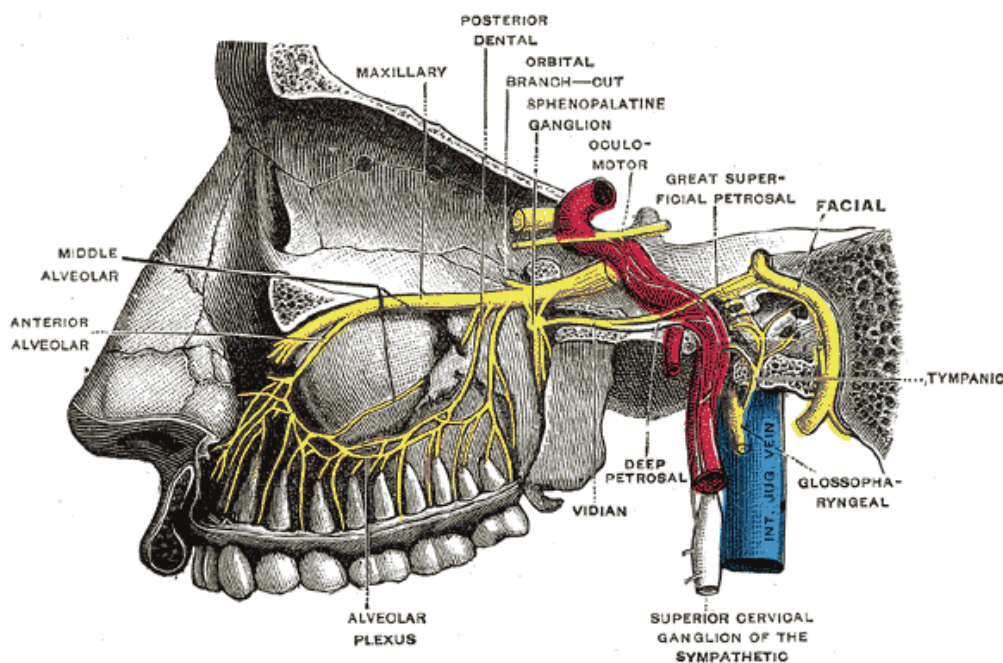
*The sphenopalatine ganglion has been infrequently implicated in vague symptoms of the head, face, gums, teeth, neck and back since the early 1900s.*

By Edwin A. Ernest, III, DMD, FAANAOS

The autonomic features often found to often be a part of the pain complex associated with the sphenopalatine ganglion tend to confound the clinician attempting to diagnose the reason for the patient's headache that is typically described as a dull ache.

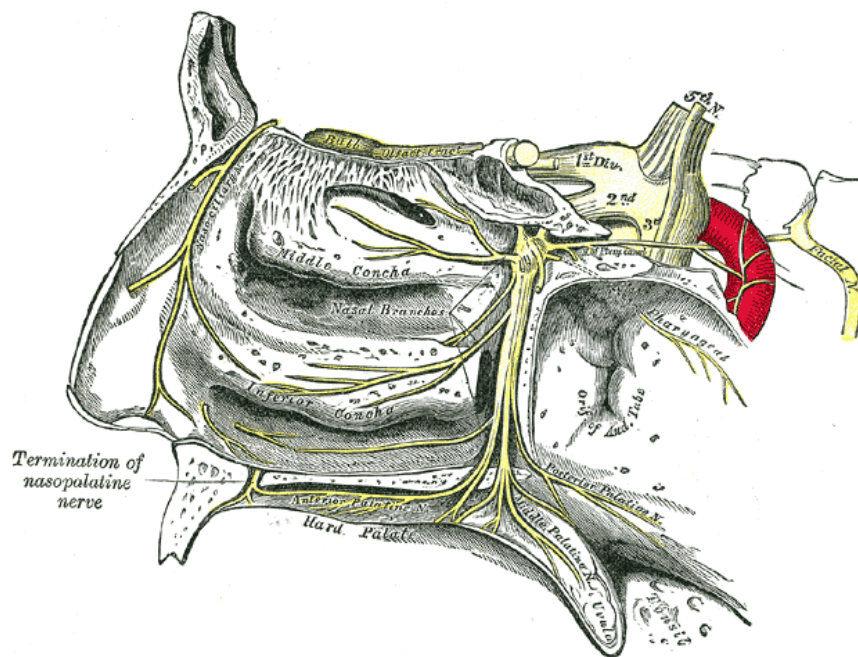
Commonly, the person suffering pain associated with the sphenopalatine ganglion also has dental symptoms, characterized as aching tooth or teeth, with the adjacent gum tissue hurting as well. This paper will describe the neuroanatomy and signs and symptoms common to the disorder, and suggests testing of the ganglion when there is headache and/or dental pain that is otherwise undiagnosed.

**Anatomy.-** The sphenopalatine ganglion—also known as pteryopalatine ganglion, Meckel's ganglion, Sluter's ganglion and nasal ganglion—is the largest of the four parasympathetic ganglia associated with the trigeminal nerve and consists of the largest collection of neurons in the head outside of the brain and is the only ganglion exposed to the environment via the nasal mucosa. It is found in the pteryopalatine fossa behind the middle turbinate of the nose and is noted to be triangular in shape. The ganglion is located just below the maxillary nerve as the maxillary nerve crosses the fossa. The sphenopalatine ganglion receives three nerve roots: the sensory root from the sphenopalatine branches of the maxillary nerve, the motor root derived from the nervus intermedius which is a part of the facial nerve through the greater petrosal nerve, and the sympathetic root, which consists of sympathetic postganglionic (efferent) fibers from the superior cervical ganglion (see Figure 1).



**Figure 1.** Alveolar branches of superior maxillary nerve and pterygopalatine ganglion. (From Gray's Anatomy as presented on Wikipedia.<sup>1</sup>)

The ganglion also has preganglionic parasympathetic fibers which synapse with neurons whose postganglionic axons, vasodilator and secretory fibers are distributed with the deep branches of the trigeminal nerve to the mucous membrane of the nose, soft palate, tonsils, uvula, roof of the mouth, upper lip and gums, possibly teeth, and to the upper part of the pharynx (see Figure 2). Postganglionic parasympathetic fibers also go to the lacrimal gland via a branch of the maxillary nerve which then connects with a branch of the ophthalmic nerve (lacrimal nerve) arriving at the lacrimal gland. The palatine nerves send secretomotor fibers to the nasal glands and to the pharyngeal glands and all are branches of the maxillary nerve.



**Figure 2.** The pterygopalatine ganglion and its branches.

## Discussion

The sphenopalatine ganglion has been associated with a wide variety of pain problems that range from pain in the head and neck, gums and maxillary teeth, to pain of the low back. Beginning with the early part of the twentieth century, Sluder reported the first case of headache being relieved by sphenopalatine ganglion block with local anesthetic.<sup>2-10</sup> A variety of conditions should be considered for vague pain of the head and neck: migraine, cluster, tension, mixed headache, facial neuralgias, and musculoskeletal pain such as temporal tendonitis. In fact, the case that is presented in this paper was referred for right side temporal tendon pain, yet blocking of the painful tendon did not affect the pain.

Pain of the mid-face region is often a difficult issue for those who hurt and those who bear the responsibility to provide care. How do you diagnose vague symptoms that range from achy teeth and gums associated with the right maxillary arch, headache, and profuse sweating when the pain is most intense. The pain may often start in the gum

tissue where a maxillary molar tooth was extracted earlier. In fact, three molar teeth were extracted thinking that the teeth were the source of the patient's intractable symptoms. To the casual observer, this type of patient would need to see a dentist or oral surgeon for a better examination than the patient has had previously. Unfortunately, the patient had seen several dentists and the treatment was extraction of the maxillary right first, second and third molars.

## Case Report

A well-nourished white male, age 58, was referred for evaluation of right-sided headache possibly associated with temporal tendonitis. Mandibular vertical range of motion was within normal limits as were the mandibular lateral movements of the mandible. Digital palpation of the right temporal tendon was painful and right side hemicranial headache was present. The patient had three molar teeth extracted five months earlier because of the pain, but the removal of the teeth did not stop the pain, and the intra-oral pain simply moved from the teeth to the gum tissue adjacent to the extraction sites. At the time of examination, the patient had headache that was rated as a seven on the visual analog scale. The patient noted during the exam that the use of Orajel<sup>®</sup> on the gum tissue would stop the gum pain and the headache temporarily. The symptoms could suggest a variant of SUNCT Syndrome but it is not SUNCT (sudden unilateral neuralgiform head-ache with conjunctival tearing with autonomic features). He was on ten prescription medications at the time of exam, none of which provided any relief. It is interesting to note that the onset of pain always began at the maxillary right gum tissue and had been present for ten months. I infiltrated 2cc's of Marcaine<sup>®</sup> into the region of the right temporal tendon without any pain relief. Though there was musculoskeletal pain present at the temporal tendon, it was not the source of pain but was rather a referred pain site at that location.

Because of the teeth and gum-related pain, I decided to place a Marcaine-soaked 6-inch cotton tip applicator in the right nares for one minute with pressure contact to the nasal mucosa. Within five minutes, the headache that had been a seven on the VAS scale diminished to a two, and at the 10 minute mark had fully abated. The patient was seen again in 60 days on January 18, 2010 and was still pain free. At that time I decided to re-apply Marcaine on a cotton tip applicator to the nasal mucosa of the right side and it stimulated a headache for about 20 seconds and then the headache disappeared and did not return. This was evidence that stimulus of the sphenopalatine ganglion via the nasal mucosa can produce headache in some sensitive patients

The implication of the sphenopalatine neurons in producing pain in remotely located sites is likely related to the anatomical connections that play a pivotal role as a relay center of the autonomic nervous system. The superior cervical sympathetic ganglion has a connection with the upper cervical nerve roots. The cervical ganglion has a connection with the sphenopalatine ganglion via the deep petrosal nerve and the sphenopalatine ganglion is connected with the trigeminal nerve through the maxillary nerve. The inter-connections are present for referred pain to occur locally and at distant sites through the sphenopalatine ganglion and upper cervical neurons and thus offers a reasonable hypothesis as to how pain can be referred from the head and face area to the neck and upper back—and, of course, from the back and neck to the face and head, gums, and teeth. Since the sphenopalatine ganglion and its nerve axons are the only ganglion exposed to the environment via the nasal passages, it is reasonable to think that some

stimulation of the ganglion neurons that results in headache and other symptoms may be caused by noxious chemicals, viruses, or antigens introduced via the nasal mucosa.

## Conclusion

In cases of vague atypical pain patterns, I now include local anesthetic blockade of the nasal mucosa as one of my first routine tests so as to avoid the likelihood of failing to remember doing the test of the sphenopalatine ganglion. The unlikely side effects of the block include allergy to anesthetic, irritation to the nasal mucosa, or epistaxis, but it is rarely encountered. Autonomic nervous system stimuli that adversely affect the sphenopalatine ganglion that may cause headache and referred “dental” and musculoskeletal pain should be ruled out early in the diagnostic process before good teeth are extracted, migraine drugs are administered, Indomethacin for SUNCT is given, or interventional procedures for presumed trigeminal neuralgia or Temporal tendonitis<sup>11</sup> are undertaken. A clinical trial with 30 patients reported in the Journal of Pain Practice offers some promising results in the utilization of pulsed radiofrequency at the sphenopalatine ganglion for patients suffering intractable and chronic head and face pain.<sup>12</sup>

## Resources

- **1. Gray’s Anatomy Drawing of Sphenopalatine or Pterygopalatine ganglion**, as presented on Wikipedia.
- **2. Sluder G.** The syndrome of sphenopalatine ganglion neuralgia. *Am J Med Sci.* 1910. 111:868-878.
- **3. Sluder G.** *Nasal Neurology, Headaches and Eye Disorders.* Mosby. St Louis. 1927.
- **4. Ruskin SL.** Neurologic aspects of nasal sinus infection: headache and systemic disturbance and nasal ganglion origin. *Arch Otolaryngol.* 1929. 10: 337-383
- **5. Dock G.** Sluder’s nasal ganglion syndrome and its relation to internal medicine. *JAMA* 1929. 93:750-753.
- **6. Amster JL.** Sphenopalatine ganglion block for relief of painful vascular and muscular spasm with special reference to lumbosacral pain. *NY State J Med.* 1948. 48:2472-2480.
- **7. Ruskin SL.** Herpes zoster oticus relieved by sphenopalatine ganglion treatment. *Laryngoscope.* 1925. 35: 301-302
- **8. Devaghel JC.** Cluster headache and sphenopalatine block. *Acta Anaesthesiol Belg.* 1981. 32: 101-107
- **9. Kittrelle JP. Grause DS Seyhold MS.** Cluster headache:local anesthetic abortive agent. *Arch Neurol.* 1985. 42:496-498
- **10. Ruskin SL .** Control of muscle spasm and arthritic pain through sympathetic block at nasal ganglion and the use of Aneynlic Nucleotide. *Am J Dig Dis.* 1946. 13: 311-320
- **11. Ernest EA.** Temporal Tendonitis Migraine Mimic. *Pract Pain Manag.* 2006. 6(4): 58-64
- **12. Bayer E, Racz G, Miles D, and Heavener J.** Sphenopalatine Ganglion Pulsed Radiofrequency Treatment in 30 Patients Suffering from Chronic Face and Head Pain. *Pain Practice.* 2005. 5(3): 223-227